

A 53-YEAR-OLD MAN WITH ATYPICAL CHEST PAIN AND DEEP T WAVE INVERSION

M E H Tan, W S Teo

CASE HISTORY

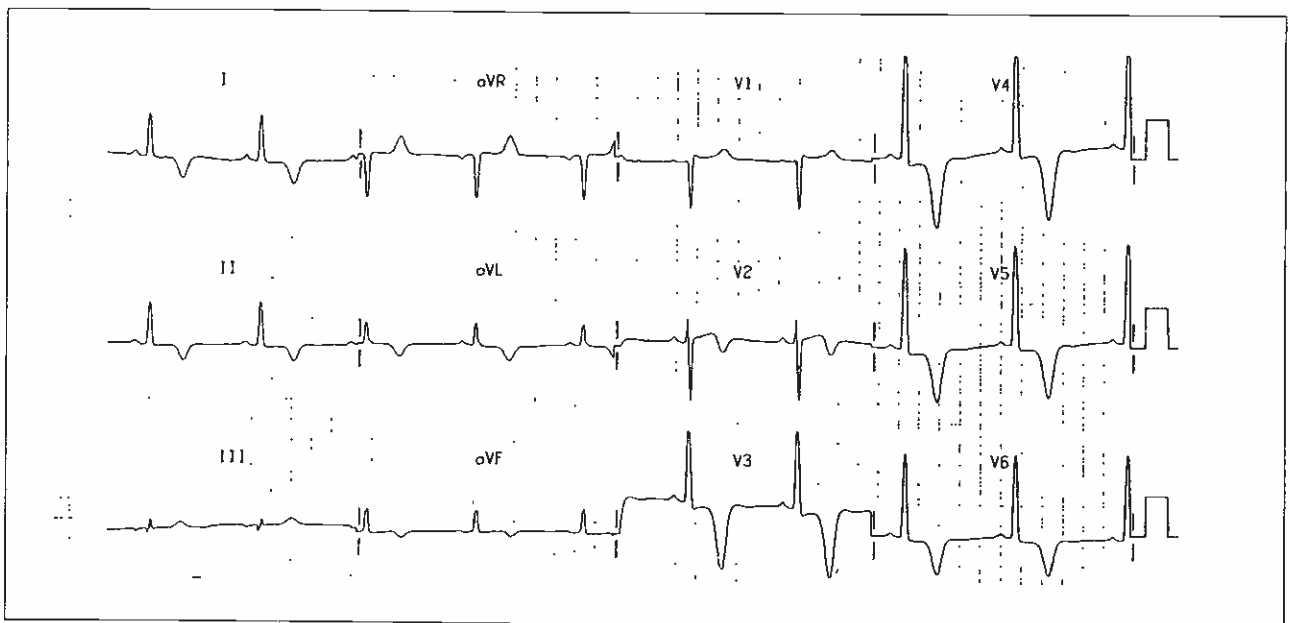
Mr MK, a 53 year-old man, first presented in 1979 with a history of left precordial chest pain. This was described as a burning sensation, constant in nature with no radiation and no aggravating factors. He has a strong history of heart disease and sudden cardiac death in the family. There were no other coronary artery disease risk factors. Clinical examination revealed a healthy, well-built man with stable vital signs. The pulse was regular and the apex beat normal in position and character. On cardiac auscultation, the first and second heart sounds were heard and an occasional S4 gallop was also noted; no murmurs were audible.

His 12 lead electrocardiogram is shown below:

What is your diagnosis? (Answer on Page 422)

SINGAPORE MED J 1992; Vol 33: 400 & 422

Fig 1 - The 12 lead electrocardiogram of the patient



Department of Cardiology
Singapore General Hospital
Outram Road
Singapore 0316

M E H Tan, MBBS(S'pore), MRCP(Ireland)
Registrar

W S Teo, MBBS(S'pore), MRCP(UK), M Med(Int Med)
Senior Registrar

Correspondence to: Dr W S Teo