

## PORPHYRIA CUTANEA TARDA SIMULATING SCLERODERMA

C L Goh

### SYNOPSIS

Porphyria cutanea tarda (PCT) is an uncommon metabolic disease in Singapore. 2 cases of porphyria cutanea tarda with pseudoscleroderma is described. Both presented with sclerodermatous skin lesion associated with mottled pigmentation of the face, limbs and trunk. Other features of porphyria cutanea tarda such as hirsutism and photosensitivity were absent. The skin lesion in both patients simulates scleroderma. Both patients responded to low dose oral chloroquine.

### INTRODUCTION

Porphyria cutanea tarda (PCT) is a metabolic disease clinically characterised by skin lesions due to photosensitization by porphyrins. The main biochemical feature is the excessive excretion and hepatic accumulation of uroporphyrins and porphyrins with acetate substituents. A decreased uroporphyrinogen decarboxylase activity is found in the hepatic tissue in these patients. PCT has generally been considered an acquired disorder of porphyrin metabolism although some familial cases have been reported. Environmental substances inducing PCT-like features include alcohol, iron, estrogens, phenols and hexachlorobenzene. We report here two cases of PCT presenting with pseudoscleroderma. Our experience from these 2 cases indicated that adults with sclerodermatous lesions should be screened for PCT.

Middle Road Hospital  
250 Middle Road  
Singapore 0718

C L Goh, M Med (Int Med), MRCP (UK)  
Senior Registrar

## CASE REPORTS

## Case 1

A 63 year old Chinese female presented at Middle Road Hospital in 1981 with progressive pigmentation and tightness of the skin of her face, trunk and limbs over 1 year. There was no photosensitivity. She was a cabaret hostess for 30 years before she retired 10 years ago. She used to consume about one bottle of brandy weekly then. No family history was available as she was adopted. Physical examination showed mottled pigmentation of her face, limbs and trunk. The skin on the face, neck, upper limbs and chest appeared tight. A bulla was present on her neck. There were scars on the dorsum of her hands. There were sclerodermatous plaques on her anterior chest and breast (Fig. 2). Her back and forearms were ichthyotic with typical "fish scale" appearance (Fig. 4). Her liver was enlarged, smooth, firm, palpable 3 cm subcostally. The other systems were clinically normal. Investigation showed a haemoglobin of 11.5 gm/dl with normal leucocyte counts and differential counts; ESR was 38

mm/hr. Her liver function test was normal except for a marginally raised SGPT of 47 U/l. Alpha foeto protein was negative; serum iron and total iron binding capacity were normal; antinuclear antibody negative. Urinary microscopic examination was normal. Chest X-ray and liver scan were normal. Urinary porphyrins (qualitative) test was strongly positive but porphobilinogen was negative; stool porphyrin (qualitative) test was positive. The 24 hour urinary uroporphyrins was elevated, 958.4 ug/24 hour and the coproporphyrins was 128.7 ug/24 hour (normal). Skin biopsy (Fig. 5) showed subepidermal cleft with minimal perivascular lymphocytic infiltrate. The epidermis was atrophied. There was increased collagen in the dermis and with scarcity of skin appendages. The dermal vessels showed PAS positive hyaline cuffing.

The patient was treated for PCT with chloroquine 150 mg 2 times a week for about 6 weeks and then defaulted. She was recalled 3 years later and was found to be well; her pigmentation had diminished and her skin less tight. Her urinary porphyrins test became negative.

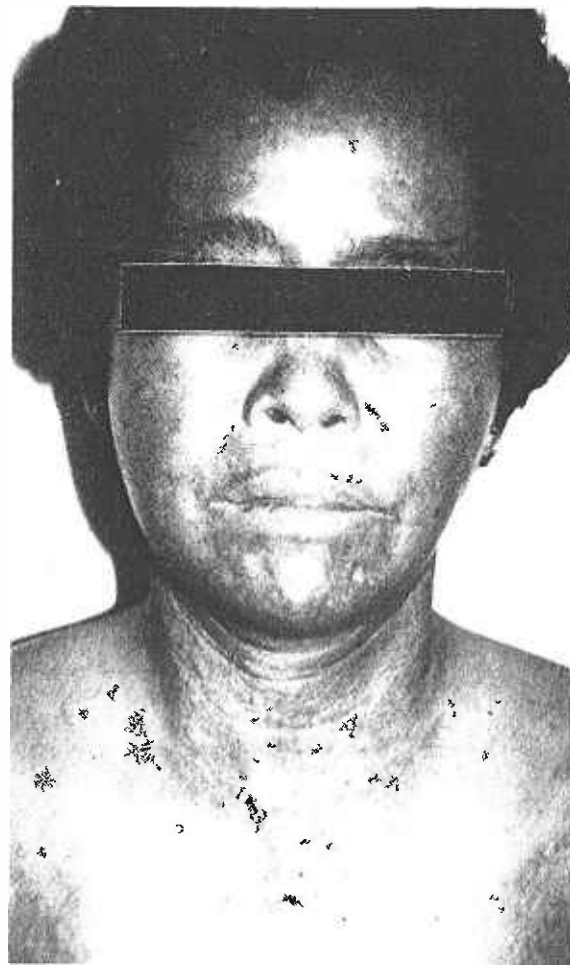

Fig. 1. Case 2. Porphyria cutanea tarda with mottled pigmentation of the face and tightness of skin. Note sclerodermatous plaques on anterior neck.

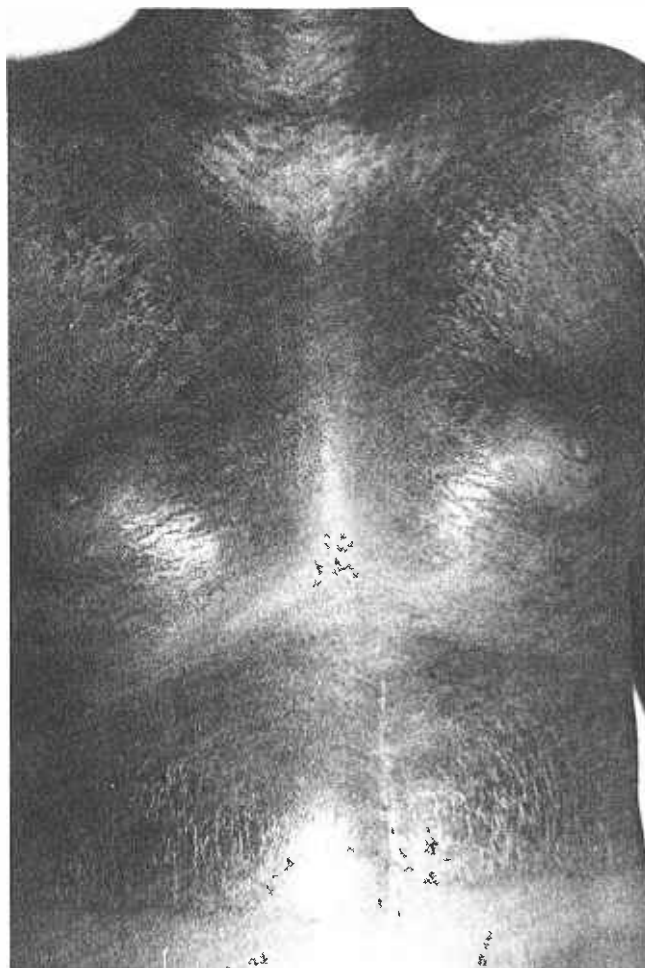


Fig. 2. Case 1. Porphyria cutanea tarda with sclerodermatous plaques an anterior chest and breast.

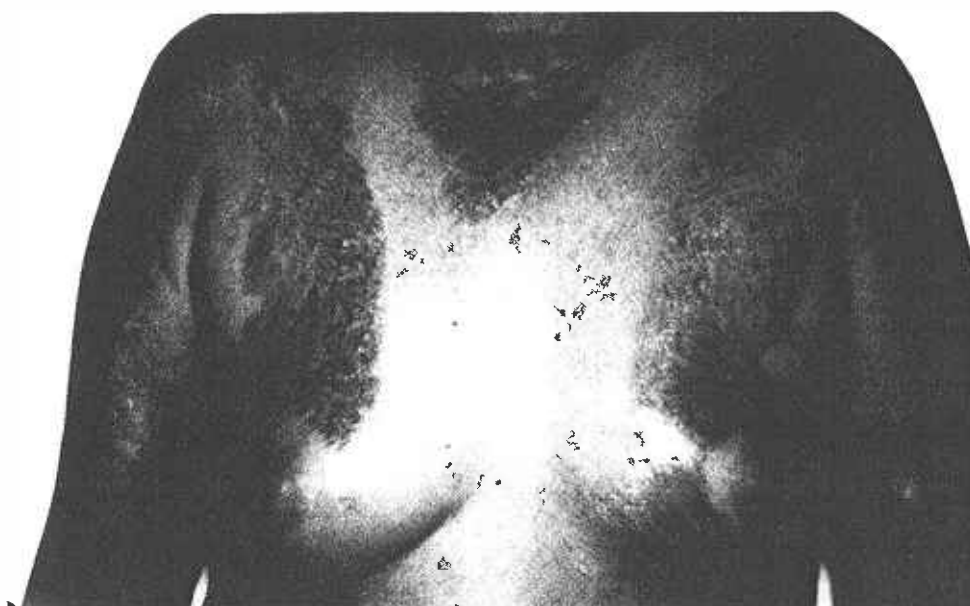

Fig. 3. Case 2. Porphyria cutanea tarda on anterior chest and breast. Note similarity of distribution of plaques to case 1.

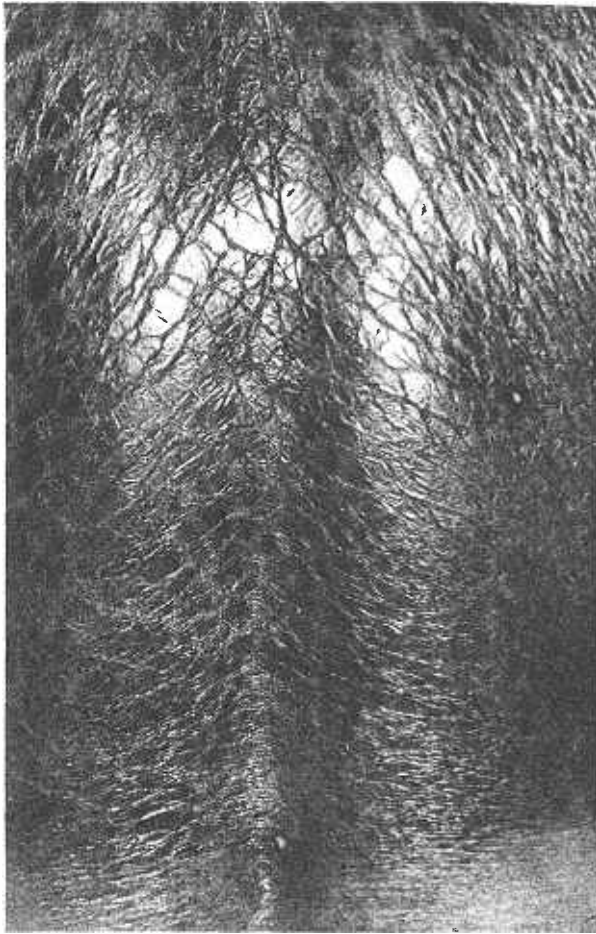


Fig. 4. Porphyria cutanea tarda with acquired ichthyosis of the back (Case 1). Ichthyosis has not been reported to be an associated feature of porphyria cutanea tarda.

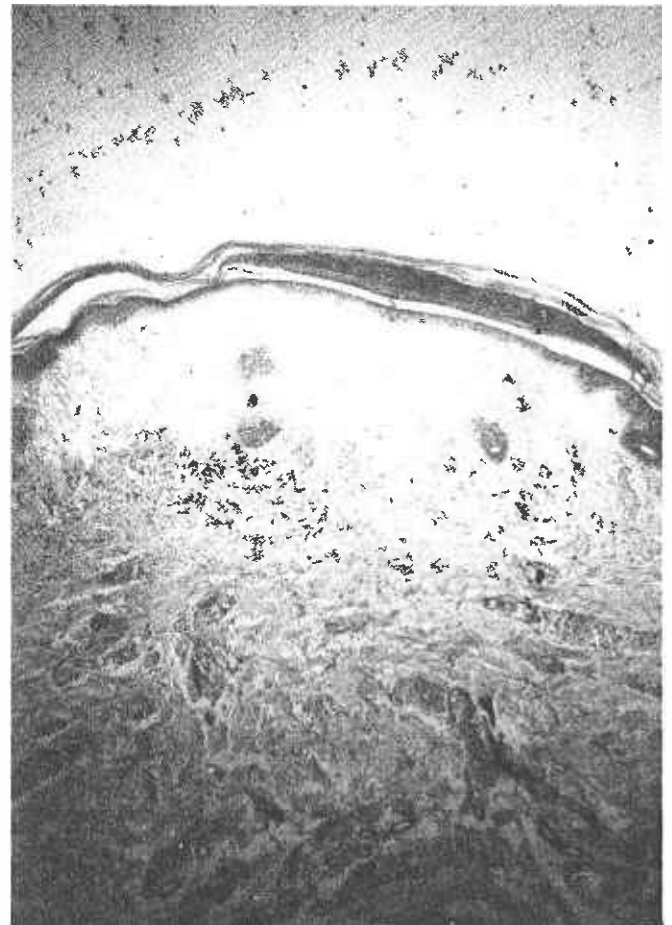

Fig. 5. Histology of the skin (Case 1). Note subepidermal blister with minimal upper dermal infiltrate. There is hyaline cuffing of the upper dermal vessels on Periodic Acid Schiff stains, characteristically seen in porphyria cutanea tarda.

## Case 2

A 51 year old Chinese female presented with progressive pigmentation of the face in December 1982. The pigmentation progressed to involve the limbs and the trunk by 1983. Over the 2 years she also noticed her skin on her face, chest and limbs becoming tight. There was no photosensitivity. Skin biopsy then showed changes consistent with scleroderma. The patient was treated for early scleroderma with oral penicillamine for about 1 year without improvement. She was reviewed by the dermatologist because of generalised pruritus. There was no significant past history of note. She was a housewife and a teetotaler. She was on aldomet for hypertension for about 1 year then. Physical examination in 1984 showed a well nourished female with mottled pigmentation on her face (Fig. 1), limbs and trunk. The skin on her face, limbs and trunk appeared tight and there were sclerodermatous plaques on her anterior neck, chest, breast (Fig. 3) and back. Her liver and spleen were not palpable. Investigation showed haemoglobin of 11 gm/dl with normal leucocyte count and normal differential counts. ESR was 23 mm/hr. Urine microscopic examination was normal. Urinary porphyrin (qualitative) test was strongly positive; stools porphyrin (qualitative) test weakly positive. Liver function test, urea and electrolytes were normal; Hepatitis B surface antigen was negative. The serum iron was marginally raised, 168 ug/dl; total iron binding capacity was 294 ug/dl; antinuclear antibody was negative. Chest X'ray, barium swallow and meal were normal and CT scan of the liver was normal. Freshly biopsied liver tissue autofluoresce orange. There was increased iron store in the hepatocytes. Skin biopsy showed changes similar to case 1 with early subepidermal bullae, mild dermal lymphocytic infiltrate and hyaline cuffing of the superficial dermal vessels.

The patient was treated for porphyria cutanea tarda and started on oral chloroquine 150 mg 2 times per week. The urinary porphyrin became negative after 6 months. Chloroquine was tailed down over 18 months and discontinued. The patient noted her pigmentation had diminished her skin less tight.

## DISCUSSION

Acquired porphyria cutanea tarda is an uncommon metabolic disease in Singapore. The presentation of pseudoscleroderma in these 2 patients should remind physicians to differentiate PCT from scleroderma. The two conditions can be differentiated by simple qualitative tests for porphyrin in urine and stool.

Gunther originally classified PCT as hematoporphyria chronica in 1911, and this condition was subsequently known as its present entity in 1937 when Waldenstrom described the condition as a distinct form of porphyria. PCT has been considered an acquired disorder of porphyrins metabolism because most of the patients do not have a family history of porphyria. Both our patients did not have a family history of PCT. Recently several family cases have been reported (1) and this has led to the belief that more than one form of PCT exists.

Kushner et al (2) suggested that patients with PCT has a specific inherited deficiency of uroporphyrinogen decarboxylase and Elder et al (3) have confirmed this in liver cell of patients with non-familial PCT.

Several environmental chemicals including hexachlorobenzene (4,5) chlorinated phenols (12), estrogens (6), iron (7), and alcohols (8) have been found to induce a PCT like syndrome by various mechanisms. Case 1 probably has acquired PCT from alcohol as she was a heavy alcohol drinker during her

younger age. She did not consent to a liver biopsy to substantiate the presence of liver disease in PCT as hepatic iron overload accompanies most cases of PCT; although raise serum iron is present in one third of PCT only (7,10). The cause of PCT in Case 2 is unknown. PCT is uncommon in Singapore although there are chronic alcoholics around. Some of these alcoholics probably have undiagnosed PCT. Routine screening of urinary porphyrins in alcoholics may reveal more cases of PCT in Singapore. The absence of inherited deficiency of uroporphyrinogen decarboxylase in our population may be another reason.

Vesicles and bullae on exposed parts of the body associated with skin fragility are common presentations of PCT. These were absent in our patients. However skin biopsies from our patients showed early subepidermal blisters. Photosensitivity is absent in our patients. The darker skin colour of Asians probably afforded greater protection against the effect of sunlight compared with the fairer Caucasians. Hyperpigmentation and hypopigmentation with mottled appearance together with sclerodermatous skin, as seen in our patients are common presenting features of PCT (11). The sclerodermatous changes that often occurs on the sun exposed parts of the limbs and occasionally on covered parts of the body (11) may be mistaken for scleroderma. The histology of these sclerodermatous lesion is usually indistinguishable from those of scleroderma. Both our patients were initially diagnosed to have scleroderma because of the skin presentation and histology of scleroderma. Hypertrichosis, another feature of PCT (12) is absent in our patients.

Acquired ichthyosis has not been reported to be a feature of PCT. But Case 1 presented with characteristic leabella ichthyosis which appeared only after her symptoms of PCT occurred. We have excluded other causes of acquired ichthyosis and there is circumstantial evidence to associate PCT with ichthyosis here. The ichthyosis unlike the pigmentation and sclerodermatous lesions did not appear to respond to chloroquine treatment.

Plebotomy (11,13,14) and low dose oral chloroquine therapy (15,16,17) are two forms of therapy recommended for treating PCT. In both therapies the aim is to remove the excess liver iron store which appeared to inhibit uroporphyrinogen decarboxylase activity. Chloroquine is hepatotoxic and should be used with caution in patients with PCT where the liver is often already abnormal. High dose oral chloroquine can cause severe hepatitis and liver failure in PCT. Both patients were treated with low dose oral chloroquine with improvement. The mode of action of chloroquine is unclear. Scholnick et al (18) showed that chloroquine binds hepatocellular porphyrins making them more water soluble. The water soluble chloroquine porphyrin complex then diffuses rapidly from the hepatocytes and is more easily excreted. Most reports on successful treatment of PCT are based on reduction in urinary porphyrins excretion but quantitative measurement of porphyrins was not available locally. Positive response to oral chloroquine was based on a negative qualitative urinary porphyrins test in our patients. It appeared that a positive response to oral chloroquine is associated with reduction of pigmentation and tightness (unfortunately these changes are not quantifiable). Our experience confirms that low dose oral chloroquine is a safe and effective treatment for acquired PCT.

The experience in these two patients showed that PCT should be excluded in patient sclerodermatous lesion. PCT should be suspected especially when the sclerodermatous changes is associated with pigmentation. Simple qualitative urinary and stool porphyrin tests (20) appeared to be good screening tests.

## ACKNOWLEDGEMENT

Drs T Thirumorthy and Ong Beng Hock arranged for quantitative estimation of urinary and stools porphyrins by Dr J Hawk of St John's Hospital for Diseases of the Skin, London of Case 1. Dr Teh Lip Bin performed the liver biopsy and Dr Jean Ho reported the history of the liver biopsy of Case 2.

## REFERENCES

1. Diez AG, Salamanca R, Herrera JF, Olmos A, Araques M, Benaverte RR: Porphyria cutanea tarda in three brothers and one sister. *Dermatologica* 1981; 162:243-8.
2. Kushner JP, Steinmuller OP, Lee GR: The role of iron in the pathogenesis of porphyria cutanea tarda II. Inhibition of uroporphyrinogen decarboxylase. *J Clin Invest* 1976; 58: 1089-97.
3. Elder GH, Lee GB, Tovey JA: Decrease activity of hepatic uroporphyrinogen decarboxylase in sporadic porphyria cutanea tarda. *N Engl J Med* 1978; 299: 274-8.
4. Schmid R: Cutaneous porphyria in Turkey. *N Engl J Med* 1960; 263: 397.
5. Rook A, Champion RH: Porphyria cutanea tarda and diabetes. *Br Med J* 1960; i: 860-1.
6. Roenigk HH, Gottlob NE: Estrogen induced porphyria cutanea tarda. *Arch Dermatol* 1970; 102: 260-6.
7. Lundvall O: The effect of replenishment of iron stores after phlebotomy therapy in porphyria cutanea tarda. *Acta Med Scand* 1971; 189: 51-63.
8. Shanley BC, Zail SS, Jonberg SM: Effect of ethanol on liver aminolevulinic acid synthetase activity in urinary porphyrin excretion in symptomatic porphyrias. *Br J Haematol* 1969; 17: 389-96.
9. Epstein JH, Tuffanelli DL, Epstein W: Cutaneous changes of porphyrias. A microscopic study. *Arch Dermatol* 1973; 107: 689-98.
10. Lundvall O: The effect of phlebotomy therapy in porphyria cutanea tarda. *Acta Med Scand* 1971; 189: 33-49.
11. Malkinson FD, Pearson RW. *Year Book of Dermatology*. Chicago, Year Book Med Publisher Inc 1975: 9-47.
12. Goldstein JA, Friesen M, Linder RE, Hickman P, Hass JR, Bergman H: Effect of pentachlorophenol on hepatic drug metabolizing enzymes and porphyria related to contamination with chlorinated dibenzo p doxins and dibenzofurans. *Biochem Pharmacol* 1977; 26: 1549-57.
13. Ramsay CA, Magnus IA, Turnbull A, Baker H: The treatment of porphyria cutanea tarda by venesection. *Q J Med* 1974; 43: 1-24.
14. Epstein JH, Redeker AG: Porphyria cutanea tarda. A study of the effect of phlebotomy. *N Engl J Med* 1968; 279: 1301-4.
15. London ID: Porphyria cutanea tarda. *Arch Dermatol* 1957; 75: 801-3.
16. Saltzer EI, Redeker AG, Wilson JW: Porphyria cutanea tarda. Remission following chloroquine administration without adverse effects. *Arch Dermatol* 1968; 98: 496-8.
17. Kordac V, Papezova R, Semradova M: Chloroquine in the treatment of porphyria cutanea tarda. *N Engl J Med* 1977; 296: 949.
18. Scholnick PL, Epstein JH, Marver HS: Soluble aminolevulinic acid synthase of rat liver. *J Biol Chem* 1972; 247: 4126-31.
19. Taljaard JF, Shanley BC, Stewart-Wynne EG, Deppe WM, Jonberg SM: Studies on low dose chloroquine therapy and the action of chloroquine in symptomatic porphyria. *Br J Dermatol* 1972; 87: 261-9.
20. Harber LC, Bickers DR. *Photosensitivity Diseases*. Philadelphia, W B Saunders Company, 1981: 346-8.