

ERRATUM

In Vol 26, No 6, October 1985 issue of the Singapore Medical Journal, the first three figures for the article entitled "Problems in Total Parenteral Nutrition In Paediatric Practice" appearing on pages 424 and 425 were printed upside down. In addition legends for all the figures are left out. We now print the corrected version.

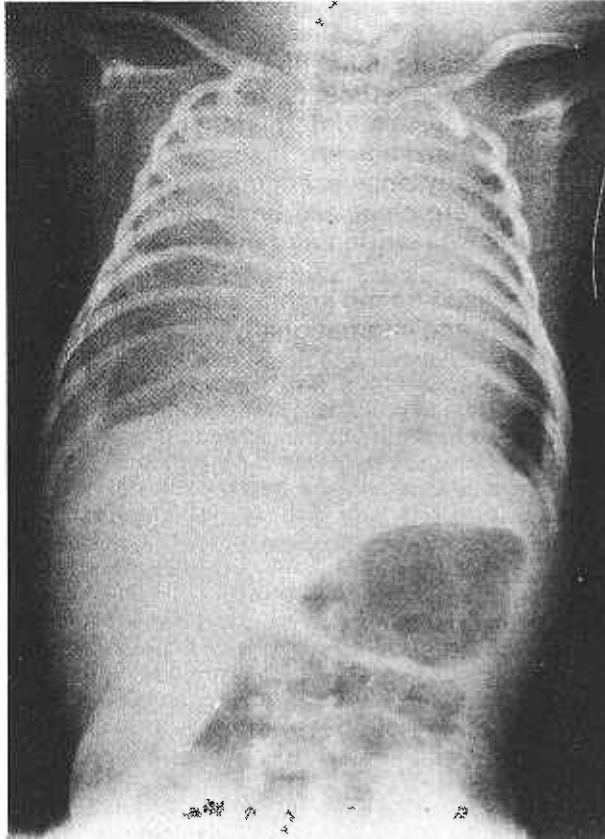


Figure 1 shows CXR with generalised opacity over the right hemithorax and shift of the cardiac shadow to the left. Note the central venous catheter.

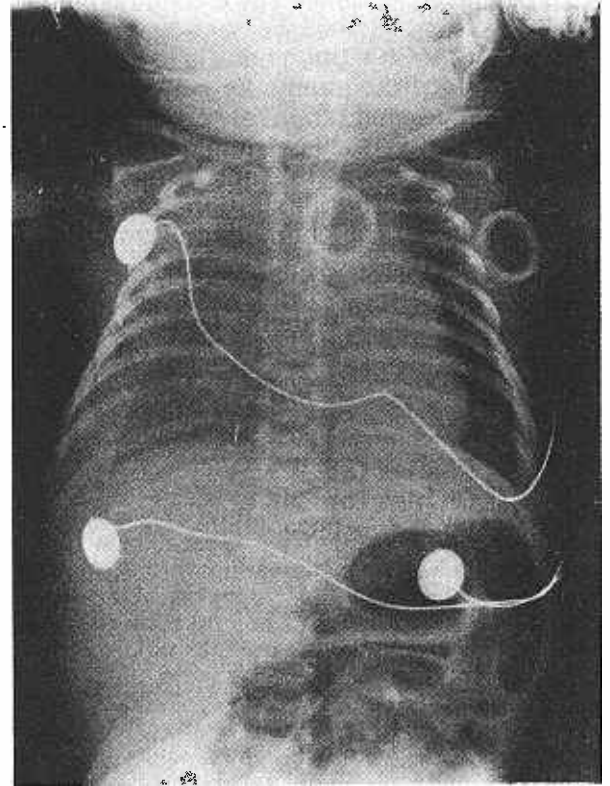


Figure 2 shows CXR of the same patient who was intubated and had 60 mls of the pleural fluid aspirated from the right pleural cavity. The left lung was better seen. The central venous line was still in situ. Note the transcutaneous monitoring sensor.

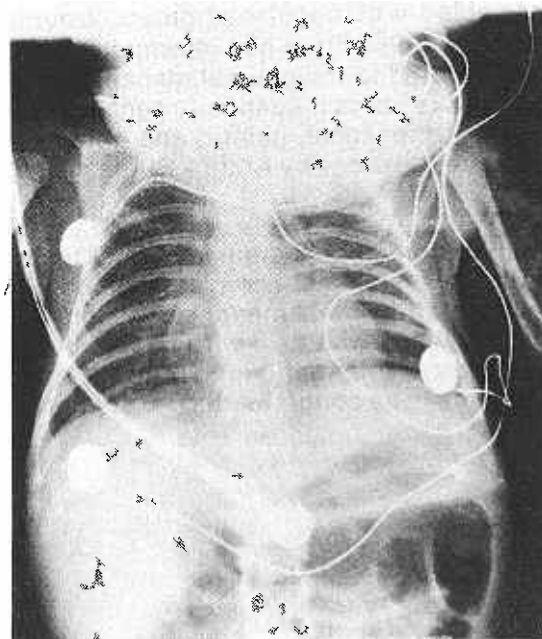


Figure 3 shows CXR of the same patient with total clearance of right pleural effusion and reexpansion of the right lung. The central venous catheter was removed.

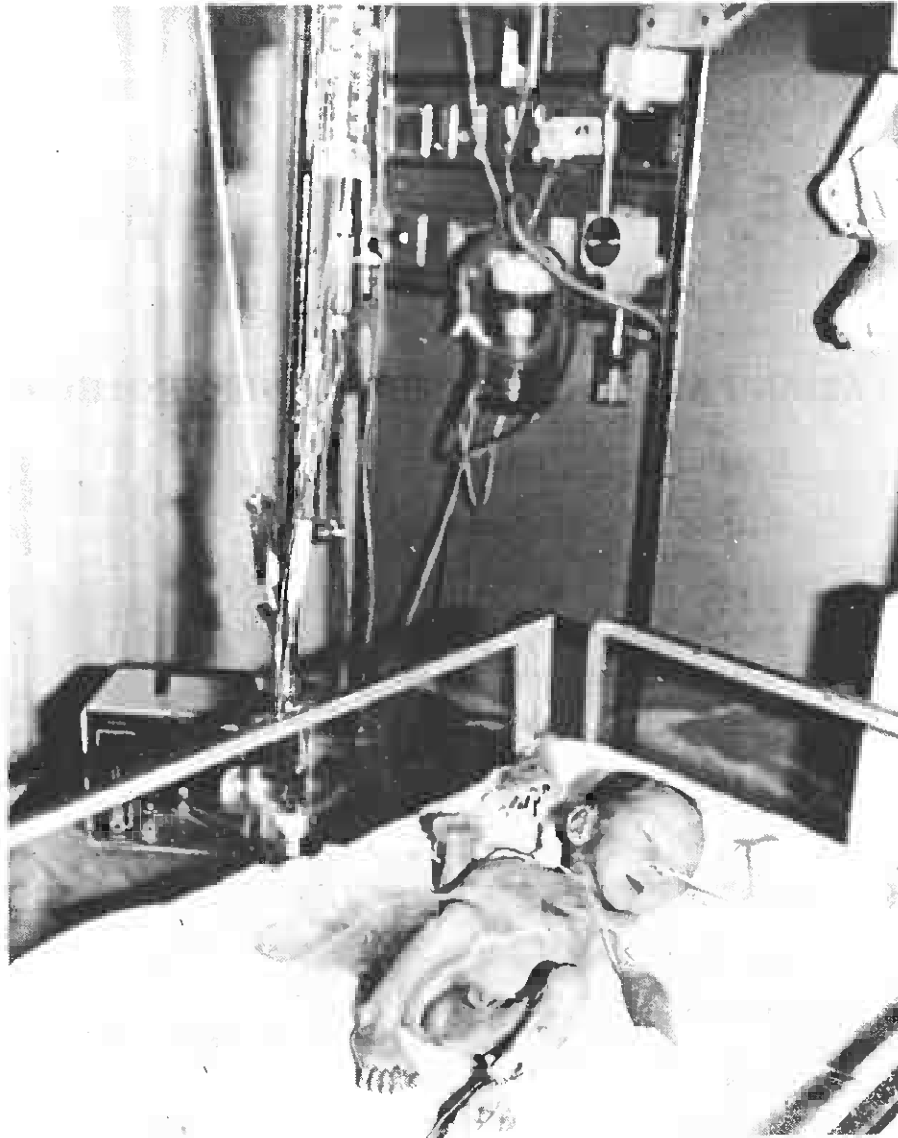


Figure 4 shows multiple Y connections which should be avoided as far as possible.



Figure 5 shows pharmacists working in the aseptic laminar flow room in Singapore General Hospital.